



# International Journal of Dermatology, Venereology and Leprosy Sciences

E-ISSN: 2664-942X  
P-ISSN: 2664-9411  
[www.dermatologypaper.com](http://www.dermatologypaper.com)  
Derma 2021; 4(2): 39-42  
Received: 28-06-2021  
Accepted: 30-07-2021

**Arpna Sharma**  
Junior Resident, Department  
of Dermatology, Venereology  
& Leprosy, Maharishi  
Markandeshwar Medical  
College & Hospital, Solan,  
Himachal Pradesh, India

**Rajwinder Singh**  
Professor, Department of  
Dermatology, Venereology &  
Leprosy, Maharishi  
Markandeshwar Medical  
College & Hospital, Solan,  
Himachal Pradesh, India

**Saurabh Sharma**  
Assistant Professor,  
Department of General  
Surgery, Maharishi  
Markandeshwar Medical  
College & Hospital, Solan,  
Himachal Pradesh, India

**Rakesh Gupta**  
Assistant Professor,  
Department of  
Ophthalmology, Maharishi  
Markandeshwar Medical  
College & Hospital, Solan,  
Himachal Pradesh, India

**Vinay Shankar**  
Professor and Head,  
Department of Dermatology,  
Venereology & Leprosy,  
Maharishi Markandeshwar  
Medical College & Hospital,  
Solan, Himachal Pradesh,  
India

**Corresponding Author:**  
**Saurabh Sharma**  
Assistant Professor,  
Department of General  
Surgery, Maharishi  
Markandeshwar Medical  
College & Hospital, Solan,  
Himachal Pradesh, India

## Nail fold capillaroscopy: A diagnostic tool for early detection of microvascular complication in diabetics without retinopathy

**Arpna Sharma, Rajwinder Singh, Saurabh Sharma, Rakesh Gupta and Vinay Shankar**

**DOI:** <https://doi.org/10.33545/26649411.2021.v4.i2a.90>

### Abstract

**Background:** Nailfold capillaroscopy is a major diagnostic tool for connective tissue disorders like systemic sclerosis. Microvascular complications in diabetes is the major cause of morbidity and mortality which if detected early can improve the quality of life of these patients.

**Materials and Methods:** A prospective, cross-sectional study enrolled 30 diabetic patients for one year. An ophthalmologist examined all participants to rule out retinopathy. All patients subsequently underwent detailed nail fold capillaroscopy (NFC) examination of all ten fingernails with digital Dermatoscope. Data was recorded and presented with proportions.

**Results:** The mean age was  $45.88 \pm 11.49$  years (p-value: 0.009) with 17 (56.1%) males and 13 (43.9%) females. Mean HbA1c was 7.1 (1.6) % (p-value: 0.074). One (1.3%) participant had abnormal nail plate, nail fold, and lunula on examination. In addition, 2 (6.7%) participants had abnormal (ragged) cuticles. The mean capillary density was  $6.72 \pm 0.38$  capillaries per mm (range 5.83-7.24). Tortuosity was the most common observed qualitative change (n=28; 93.3%) followed by meandering capillaries (n=23; 76.7%), capillary dilatation (n=15; 50.0%) and avascular areas (n=14; 46.7%).

**Conclusion:** In diabetic patients without retinopathy, nail fold changes appear before microangiopathic complications like retinopathy. Nailfold capillaroscopy is a potential early screening tool for patients at risk of microangiopathic complications.

**Keywords:** diabetes complications, microscopic angioscopy, dermoscopy, microvascular rarefaction, diabetic microangiopathy, diabetic retinopathy

### Introduction

Nailfold capillaroscopy (NFC) is a non-invasive, painless, and sensitive technique for evaluating microvascular involvement, most often in patients with Raynaud's phenomenon (RP), systemic sclerosis, and connective tissue disorders [1-3]. Furthermore, capillaroscopy is increasingly being utilized in patients with systemic disease to forecast the probability of future visceral issues and digital ulcers [4]. Capillaroscopic assessment includes quantitative changes like the capillary diameter and means capillary density. Qualitative changes include tortuosity, meandering capillaries, avascular areas, micro-hemorrhages, and neoangiogenesis at the fingers' nail fold region [3, 5].

The nail fold capillary bed gives easy access to the capillaries that run parallel to the epidermis and allows visualization of the whole capillary loop [6]. Several capillary alterations associated with diabetes and poor metabolic regulation are described. Previous studies have shown a connection between the degree of microvasculature changes and diabetes metabolic control [1, 2, 6]. Early detection of changes in capillaroscopy helps in risk assessment in diabetic patients for future microangiopathic events [1].

The purpose of this study is to study nail fold changes on capillaroscopy vis-a-vis structural capillary changes in diabetic patients without retinopathy.

### Materials and Methods

#### Study population

We conducted a prospective, cross-sectional study among 30 diabetic outpatients in the Department of Dermatology, Venereology, and Leprosy (DVL) for a year.

Diagnosis of diabetes was made as per American Diabetes Association Criteria [7] for diagnosis of diabetes were included in the study. Patients with ocular/retinal disease, Raynaud phenomenon, hypertension, collagen vascular diseases, on glucocorticoids and oral contraceptives were excluded from the study.

### Method of Data Collection

All patients recruited underwent ophthalmic examination with fundoscopy to rule out retinopathy. Demography, clinical history, findings on systemic examination, and treatment records were documented. Blood investigations followed this, i.e., renal function test (RFT), liver function test (LFT), lipid profile, urine dipstick test for micro-albuminuria, HbA1c, fasting blood sugar post-prandial values.

### NFC examination

A detailed NFC examination of all ten fingernails was conducted with the help of a digital dermatoscope. The patients were seated at a comfortable ambient temperature (22-25°C) with hands kept at the heart level. For NFC, a drop of immersion oil was applied to the proximal nail fold to maximize the translucency. The entire nail fold will then be visualized first at low power and then at high intensity.

### Quantitative Analysis

Mean capillary density was calculated by counting the number capillaries in a 4mm area in the proximal nailfold of all the fingers and dividing the value by sixteen.

### Qualitative Analysis

- *Dilatation of capillaries*: Capillaries whose width as well as afferent and efferent loop diameter appears more than that of normal capillary loop.
- *Avascular areas*: Absence of 2 or more adjacent capillary loops from the distal most capillary loops.
- *Micro-hemorrhages*: Any evidence of capillary loop thrombosis and/or extra capillary extravasates.
- *Bushy capillaries*: Capillary loops that show small and multiple buds of capillaries.
- *Meandering capillaries*: Capillaries whose limbs curl upon themselves or other capillaries.
- *Tortuous capillaries*: Capillaries whose limb curl but don't cross over each other
- Presence of *sub papillary plexus*. The cutaneous microvasculature is comprised of two plexuses: the superficial plexus, also known as subpapillary plexus, which is located in the papillary dermis; and the deep plexus located at the junction of dermis and subcutaneous tissue.

### Statistical Analysis

The data recorded were statistically analyzed using SPSS

v20 (IBM SPSS Statistics for windows, version 20.0. Armonk, NY: IBM Corp). Continuous variables were expressed as mean  $\pm$  standard deviation, whereas categorical variables were expressed as frequencies in percentages. Linear regression was used to study continuous variables and Fisher's exact test (or Chi square test) was used to compare categorical data.  $P < 0.05$  was considered statistically significant.

## Results

### Demographic and biochemical profile

The mean age of the control group was 45.88 $\pm$ 11.49 years. The association of mean capillary density with age showed a statistically significant result (p-value: 0.009).

Table 1 lists the other demographic and biochemical characteristics of the study cohort.

**Table 1:** Demographic and biochemical profile of the subjects with linear regression analysis with mean capillary density

S no	Character	Mean $\pm$ SD	P-value
1	Mean age (in years) $\pm$ SD	45.88 $\pm$ 11.5	0.009*
2	M:F ratio	17:13	0.968
3	Weight (kg)	64.07 $\pm$ 12.3	0.059
4	Height (cm)	163.30 $\pm$ 6.9	0.346
5	BMI (kg/m <sup>2</sup> )	24.58 $\pm$ 4.1	0.132
6	Mean Fasting Blood sugar (mg/dl)	122 $\pm$ 32	0.521
7	HbA1c (%)	7.1 $\pm$ 1.6	0.074
8	Duration of diabetes (years)	6.8 $\pm$ 4.1	0.193

\*p-value <0.05 was considered significant

### Nail examination

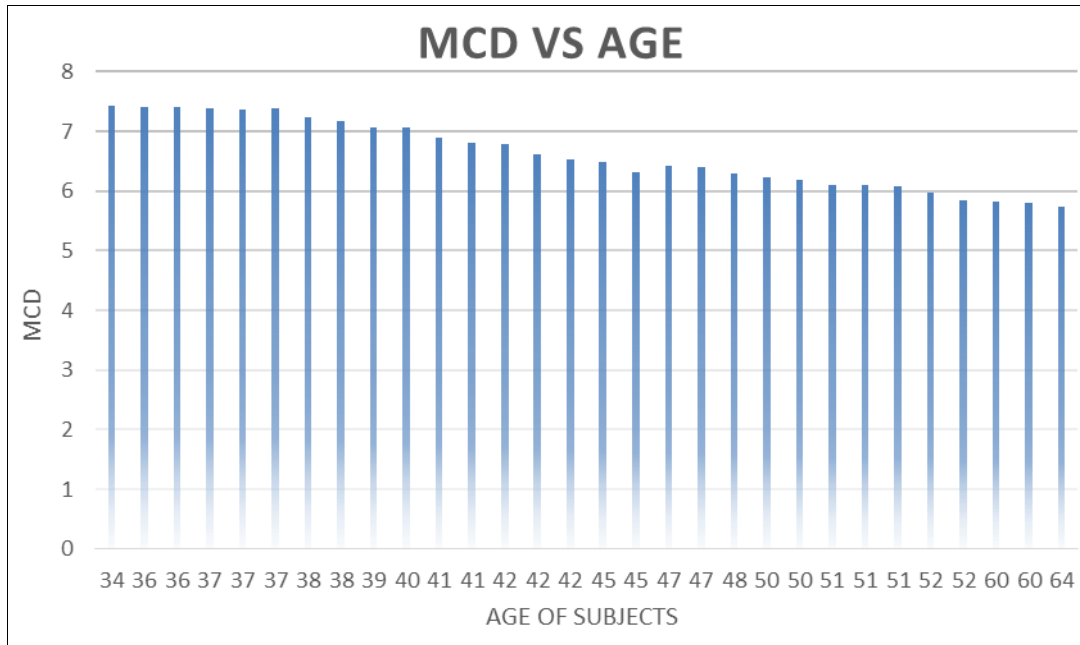
1 (1.3%) participant each had an abnormal nail plate, nail fold, and lunula. In addition, 2 (6.7%) participants had abnormal (ragged) cuticles, but none had abnormal hyponychium or nail bed. Table 2 lists the frequencies of other abnormalities noted on N.F.C.

**Table 2:** Abnormality detected in the different parts of the nail unit

S no.	Part of the nail	Abnormality detected [N (%)]
1	Cuticle	2 (6.66)
2	Nail fold	1 (1.33)
3	Nail plate	1 (1.33)
4	Lunula	1 (1.33)
5	Hyponychium	0
6	Nail Bed	0

### Quantitative Assessment

The mean capillary density was 6.72 $\pm$ 0.38 capillaries per mm (with the range of 5.83-7.24 capillaries per mm). It was 6.71 $\pm$ 0.68 (range 6.14- 7.22) capillaries per mm in males (n=17) and 6.74 $\pm$ 0.64 (range 5.83-7.24) capillaries per mm in females (n=13). The value of capillary density has a decreasing trend with an increase in age and the number of years of diabetes. (Fig. 1)



**Fig 1:** Chart Showing decreasing trend in capillary density with age of diabetic patients

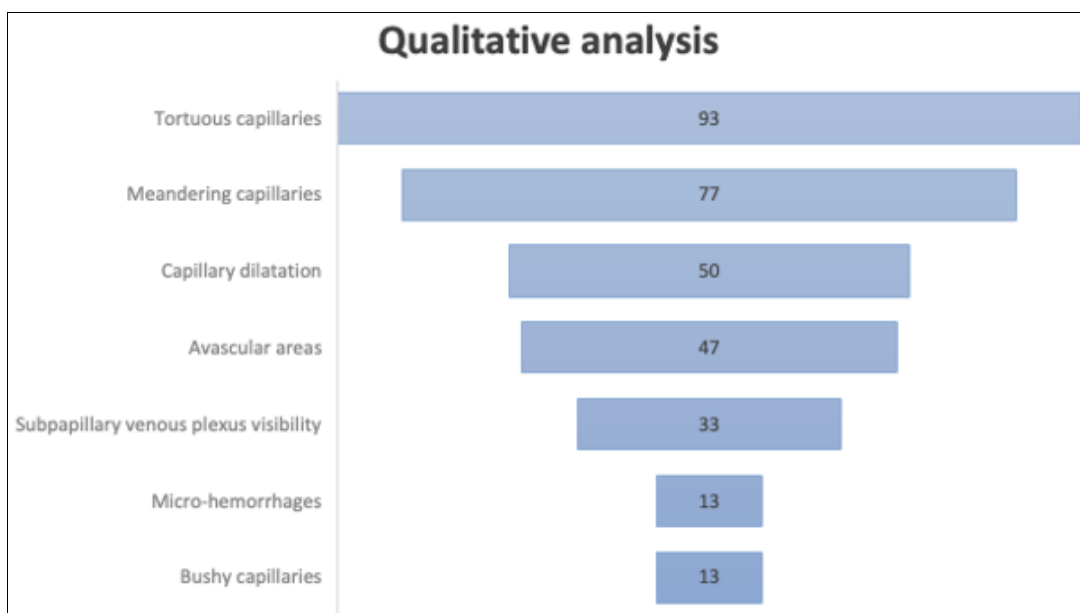
**Qualitative features**

Most common anomaly noted was tortuous capillaries (n=28; 93%) followed by meandering capillaries (n=23;

76.7%). Table 3 lists the qualitative findings, and figure 2 shows the trend.

**Table 3:** Qualitative NFC features in the study population

S no.	Qualitative features	N (%)
1	Tortuous capillaries	28 (93.3)
2	Meandering capillaries	23 (76.7)
3	Capillary dilatation	15 (50.0)
4	Avascular areas	14 (46.7)
5	Subpapillary venous plexus visibility	10 (33.3)
6	Micro-hemorrhages	4 (13.3)
7	Bushy capillaries	4 (13.3)



**Fig 2:** Chart showing Qualitative values appearing in descending order of appearance

**Discussion**

NFC is a simple, affordable and easily reproducible technique which has a crucial role to diagnose early peripheral microangiopathy in connective tissue diseases

like Raynaud’s phenomenon, systemic sclerosis etc. However, its role in diabetes mellitus is still under evaluation with promising initial results. Previous studies evaluating nailfold capillary changes in diabetes found a

high frequency of capillary alterations in diabetic individuals, including increased tortuosity of vascular loops and angiogenesis<sup>[1, 8]</sup>. Kaminska-Winciorek *et al.* discovered an increased incidence of twisted (meandering) capillaries in diabetic individuals<sup>[2]</sup>. Meyer *et al.* discovered that capillary diameters of the apical and venous limbs were increased in participants having diabetes<sup>[9]</sup>. Pazos-Moura *et al.* also found a greater incidence of expanded (dilated) capillaries and nodular apical elongation (microhemorrhages) in type 2 diabetes individuals with persistent clinical problems<sup>[10]</sup>. Barchetta *et al.* demonstrated that microcirculation changes indicated by NFC were independent of age and gender in diabetic individuals<sup>[11]</sup>. Maldonado G *et al.* described a specific pattern consisting of capillary dilatation, avascular zones, and tortuous capillaries in patients with diabetes mellitus and concluded that capillaroscopy can be used as a tool for the examination of early vascular damage and progression in Diabetes Mellitus<sup>[12]</sup>.

We found a high prevalence of tortuosity, meandering capillaries, capillary dilatation and avascular zones in the cohort. This is in line with the specific pattern described by Maldonado G *et al.* but the interesting fact was that their study population included patients with retinopathy. This shows that the changes in nailfold capillaries precedes the changes in retinal vessels thus these NFC findings could be an early alarming sign for future microvascular complication of the retina. Incidence of subpapillary venous plexus visibility was also high in the cohort compared to other studies but this can be due to the fact the appearance of the sub-papillary venous plexus may be affected by local circumstances such as hyperkeratosis, skin pigmentation, lesions, and edema<sup>[3]</sup>. This parameter was apparent in 10 (33.33 percent) of our study patients. Furthermore, we discovered avascular regions in 46.67% of the patients. Hosking *et al.* found increased avascular areas and microhemorrhages in diabetic individuals ( $t = 2.33$ ,  $P = 0.03$ ), consistent with our findings. They also discovered a link between recent HbA1c and the frequency of microhemorrhages ( $r = 0.44$ ,  $P = 0.03$ )<sup>[6]</sup>. In our study, though the frequency of NFC findings was more in the patients with HbA1c >7% but the result did not reach statistical significance ( $p$ -value: 0.193), this could be resolved by including larger number of individuals.

The major strength of our study is that it is one of the first to evaluate the NFC changes in adult Indian population with rural background where incidence of diabetes is more and access to health facility is difficult. Though the finding of tortuous capillary and rarefaction was high in the study cohort, similar to other study, but an interesting finding was that there was a significant association of these finding with age. On further evaluation to differentiate whether this observation was due to longer duration of diabetes, we found that the result of NFC changes was not statistically significant. Though, due to small number of study subjects this observation still needs more evaluation with prospective study including populations with large sample size and different ethnicity.

## Conclusion

In diabetic patients, nail fold changes precede retinopathy. Nailfold capillaroscopy thus has a potential diagnostic role in identifying the patients at risk of these microangiopathic complications early.

## References

1. Kuryliszyn-Moskal A, Dubicki A, Zarzycki W, Zonnenberg A, Górska M. Microvascular abnormalities in capillaroscopy correlate with higher serum IL-18 and sE-selectin levels in patients with type 1 diabetes complicated by microangiopathy. *Folia histochemica et cytobiologica* 2011;49(1):104-10.
2. Kaminska-Winciorek G, Deja G, Polańska J, Jarosz-Chobot P. Diabetic microangiopathy in capillaroscopic examination of juveniles with diabetes type 1. *Advances in Hygiene & Experimental Medicine/Postepy Higieny i Medycyny Doswiadczalnej* 2012;66:51-9.
3. Ingegnoli F, Gualtierotti R, Lubatti C, Bertolazzi C, Gutierrez M, Boracchi P *et al.* Nailfold capillary patterns in healthy subjects: a real issue in capillaroscopy. *Microvascular Research* 2013;90:90-5.
4. Senet P, Fichel F, Baudot N, Gaitz JP, Tribout L, Frances C. Nail-fold capillaroscopy in dermatology. *In Annales de Dermatologie et de Vénérologie* 2014;141(6-7):429-437.
5. Lambova SN, Hermann W, Müller-Ladner U. Comparison of qualitative and quantitative analysis of capillaroscopic findings in patients with rheumatic diseases. *Rheumatology international* 2012;32(12):3729-35.
6. Hosking SP, Bhatia R, Crock PA, Wright I, Squance ML, Reeves G. Non-invasive detection of microvascular changes in a paediatric and adolescent population with type 1 diabetes: a pilot cross-sectional study. *BMC endocrine disorders* 2013;13(1):1-9.
7. American Diabetes Association. Classification and diagnosis of diabetes: Standards of Medical Care in Diabetes-2019. *Diabetes Care* 2019;42(1):13-28.
8. Weinges KF. Microcirculation and hemorheology of children with type I diabetes. *Blood Fluidity and Endothelial Influences on Microcirculation* 1986;64:962.
9. Meyer MF, Pfohl M, Schatz H. Assessment of diabetic alterations of microcirculation by means of capillaroscopy and laser-Doppler anemometry. *Medizinische Klinik (Munich, Germany)* 1983;2001;96(2):71-7.
10. Pazos-Moura CC, Moura EG, Bouskela E, Torres-Filho IP, Breitenbach MM. Nailfold capillaroscopy in diabetes mellitus: morphological abnormalities and relationship with microangiopathy. *Brazilian journal of medical and biological research= Revista brasileira de pesquisas medicas e biologicas* 1987;20(6):777-80.
11. Barchetta I, Riccieri V, Vasile M, Stefanantoni K, Comberiat P, Taverniti L *et al.* High prevalence of capillary abnormalities in patients with diabetes and association with retinopathy. *Diabetic Medicine* 2011;28(9):1039-44.
12. Maldonado G, Guerrero R, Paredes C, Ríos C. Nailfold capillaroscopy in diabetes mellitus. *Microvascular research* 2017;112:41-6.