



International Journal of Dermatology, Venereology and Leprosy Sciences

E-ISSN: 2664-942X

P-ISSN: 2664-9411

www.dermatologypaper.com

Derma 2021; 4(1): 112-115

Received: 03-01-2021

Accepted: 08-03-2021

Dr. Anvitha C

Assistant Professor,
Department of DVL, Subbaiah
Institute of Medical Sciences
Shimoga, Karnataka, India

Dr. Srinivas S

Associate Professor,
Department of DVL, Subbaiah
Institute of Medical Sciences
Shimoga, Karnataka, India

Corresponding Author:

Dr. Srinivas S

Associate Professor,
Department of DVL, Subbaiah
Institute of Medical Sciences
Shimoga, Karnataka, India

Trichoscopic features of androgenic alopecia and telogen effluvium

Dr. Anvitha C and Dr. Srinivas S

DOI: <https://doi.org/10.33545/26649411.2021.v4.i1b.78>

Abstract

Introduction: Hair loss is a cause of emotional and mental distress, especially in the modern age of social media. Hair loss can be classified as Cicatricial and Non-Cicatricial, based on the permanence of the damage wrought to the hair follicles. The conditions selected for evaluation in this particular study are androgenetic alopecia and telogen effluvium, owing to their higher rate of incidence and their amenable response to timely intervention.

Trichoscopy aids in diagnosis, determination of biopsy site and acts as a prognostic tool. In this study, we will enumerate trichoscopic features of the scalp in androgenic alopecia (AGA) and telogen effluvium (TE) on the basis of follicular patterns, interfollicular patterns and hair signs

Material and Methods: It is a cross-sectional and observational study is suited for estimating the prevalence of each trichoscopic feature in AGA and TE. The study was conducted in the Department of Dermatology, Venereology and Leprosy, Subbaiah Institute of Medical Sciences, Shimoga, Karnataka. The study was conducted between January 2020 to December 2020 with sample size of 100 patients.

Results: In the 100 cases of AGA and TE, 69% had AGA and 31% TE. Hair pull test was positive in 90% patients of TE. Yellow dots (69%), empty hair follicles, (65%) peripilar sign (71%), vellus hair (95%) and variation in hair shaft diameter in frontotemporal areas (98%) are the characteristic findings in AGA patients. The follicular features present in TE are peripilar sign (10%), yellow dots (29%) and vellus hair (30%). The characteristic finding is that the variation in hair – shaft diameter is prevalent in fronto-temporal (15%) and occipital areas (65%).

Conclusion: The characteristic follicular features on Trichoscopy observed in AGA were peripilar sign, yellow dots and empty hair follicles. The characteristic hair shaft pattern observed was vellus hair. Variation in hair shaft diameter was more prevalent in fronto-temporal areas. TE is said to be a disease of exclusion on Trichoscopy. It is important to differentiate this condition from AGA, where-in the variation in hair shaft thickness is present in fronto-temporal areas and absent in occipital area.

Keywords: Dermoscopic findings of scalp, non-cicatricial alopecia, androgenetic alopecia, telogen effluvium

Introduction

Hair loss is a cause of emotional and mental distress, especially in the modern age of social media. Hair loss can be classified as Cicatricial and Non-Cicatricial, based on the permanence of the damage wrought to the hair follicles ^[1]. The conditions constituting cicatricial alopecia are lichen planopilaris, discoid lupus erythematosus, dissecting cellulitis of scalp, folliculitis decalavans.

The conditions constituting non-cicatricial alopecia are androgenetic alopecia, alopecia areata, telogen effluvium ^[2]. The appropriate and timely evaluation of these conditions will aid in successful management of these conditions. The conditions selected for evaluation in this particular study are androgenetic alopecia and telogen effluvium ^[3], owing to their higher rate of incidence and their amenable response to timely intervention. The methods to evaluate hair loss are non-invasive (trichoscopy, daily hair count, trichoscan), semi-invasive (trichogram) and invasive (scalp biopsy) ^[4].

Trichoscopy aids in diagnosis, determination of biopsy site and acts as a prognostic tool. In this study, we will enumerate trichoscopic features of the scalp in androgenic alopecia (AGA) and telogen effluvium (TE) on the basis of follicular patterns, interfollicular patterns and hair signs ^[5].

Material and Methods

It is a cross-sectional and observational study for estimating the prevalence of each trichoscopic feature in AA and TE. The study was conducted in the Department of Dermatology, Venereology and Leprosy, Subbaiah Institute of Medical Sciences, Shimoga, and Karnataka. The study was conducted between January 2020 to December 2020 with sample size of 100 patients, based on previous records of patients having AGA and TE who had attended the outpatient department of Dermatology, Venereology and Leprosy in the previous year.

Inclusion criteria: All consenting male and female patients, with AGA and TE.

Exclusion criteria: Patients having scarring alopecia or alopecia secondary to drugs and external injury were excluded from the study. Patients having non-cicatricial alopecia other than AGA and TE were also excluded from the study.

Data collection: A detailed history regarding the age, sex, occupation, family history, personal habits, duration of the disease and history of previous treatment was taken. Clinical photographs of the lesions were taken. Dermatological and systemic examination was carried out. Diagnosis of AGA and TE was made on clinical examination and by performing Hair pull test. The alopecia's were graded/classified corresponding to the type of alopecia. Modified Hamilton-Norwood scale was used for male AGA [6] and Ludwig's scale was used for female pattern hair loss [7]. Telogen effluvium was classified as Acute or chronic based on the duration of alopecia [8]. Dermoscopic/Trichoscopic examination of the scalp and hair was performed using a video dermatoscope (Dermaindia) which is a non-contact dermatoscope providing 50X and 200X magnification [9]. Six areas of the scalp; bilateral fronto-temporal, bilateral parieto-temporal, occipital and vertex areas were examined using 50X magnification in androgenic alopecia and telogen effluvium. The data was noted in a pre-tested and pre-designed proforma after taking informed and written consent.

Statistical Method for Data Analysis: Percentages were used to determine the prevalence of each trichoscopic feature in AGA and TE. Chi square test was used wherever applicable.

Results

1. Prevalence of AGA and TE

Of the 100 cases of non-scarring alopecia, AGA constituted 69%, in which 12% was contributed by AGA 1; 20% by AGA 2; 22% by AGA 3; 6% by AGA 3V; 1% by AGA 3A; 3% by AGA 4; 4% by L1 and 1% by L2. TE was found in 31% of the patients, out of which 67% of them had AcTE and 23% had ChTE.

2. Sex distribution

Out of the 100 patients that were included in the study, the percentage of male patients having AGA was 89.4% and the percentage of female patients having AGA was 10.6%. The percentage of male patients having TE was 4.8% and the percentage of female patients having the same was 95.2%

3. Prevalence of Hair Pull Test

Hair pull test was performed on all the patients involved in the study and 6.38% patients with AGA and 90% patients with TE showed positive results.

4. Prevalence of Yellow Dots

On Trichoscopic Examination of six areas of the scalp, (bilateral fronto-temporal, bilateral parieto-temporal, vertical and occipital) yellow dots were present (≥ 1 field or; < 4 fields or) in 69% patients of AGA and 29%. The above data suggests that yellow dots are present in increasing frequency in AGA (69%) than in TE (29%).

5. Prevalence of Empty Hair Follicles

Empty hair follicles were a common finding in 65% patients of AGA and no patients of TE.

6. Prevalence of Peripilar Hair

Clinical Diagnosis	Present	P%
AGA	47	71%
TE	9	30%

The above data suggest that vellus hair is more common in AGA than TE.

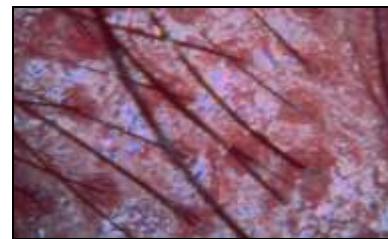


Fig 1: Peripilar sign

7. Prevalence of vellus hair

Clinical Diagnosis	Present	P%
AGA	66	95%
TE	3	10%

The above data suggest that vellus hair is a characteristic feature of AGA.

8. Prevalence of Variation in Hair Diameter (Fronto-Temporal Area)

Clinical diagnosis	Present	P%
AGA	68	98%
TE	5	15%

The above data suggests that variation in Hair Diameter (Fronto-Temporal Area) is specifically found in AGA in this study.



Fig 2: Vellus hair and variation in diameter of hair follicles

9. Variation in Hair Diameter (Occipital Area)

Clinical Diagnosis	Present	P%
AGA	1	2%
TE	20	65%

The above data suggest that variation in hair shaft diameter in occipital area is predominantly found in TE.

Discussion

Dermoscopy has received considerable interest in the recent years, with special consideration to Trichoscopy. Various instruments are being used for Trichoscopy i.e. non-contact and contact. The trichoscopic findings in alopecia's has not yet been standardized. Hence, this study has been done to detect the most common trichoscopic features in AGA and TE. Here we have compared the present study with a few related studies.

Trichoscopic Features

1. Follicular features

A. Yellow dots

The prevalence of yellow dots in AGA in the present study is comparable to that of Vivek V Nikam and Hita H Mehtas' study and the study done by Lidia Rudnicka, *et al.*

B. Empty hair follicles

The prevalence of empty hair follicles in AGA in the present study is much higher than the study by Vivek V Nikam and Hita H Mehtas' study ^[10]. This difference is perhaps due to the difference in sample size and the dermoscope used.

C. Peripilar sign

The prevalence of peripilar sign in AGA in the present study is comparable to the studies done by Vivek V Nikam and Hita H Mehta and Lidia Rudnicka, *et al.* ^[11].

2. Interfollicular pattern

The dermoscope used in the present study was not suitable to study interfollicular features like pigment and vascular patterns due to the excessive glare from the white light. Hence no comments can be made about the interfollicular features.

3. Hair shaft characteristics

A. Vellus hair

The prevalence of vellus hair in the present study in AGA is higher than that found in the study done by Vivek V Nikam and Hita H Mehta and by Lidia Rudnicka, *et al.* This variation can be explained by the diversity in types of AGA present in both the studies and the time duration of the disease in the patients enrolled in both the studies. No similar studies were found about TE in the literature.

B. Variation in hair shaft thickness (Fronto-temporal area)

The prevalence of variation in hair shaft diameter in AGA in the present study is higher than that seen in the study by Adriana Rakowska, *et al.* ^[12]. This may be because the patients having AGA enrolled in the present study were both male and female, whereas only 32 patients having FAGA were enrolled in the study by Adriana Rakowska, *et al.* It is however evident that the variation in hair shaft thickness in

Fronto-temporal area is more in AGA than TE.

Conclusion

This study showed that among 100 patients with non-cicatricial alopecia, the majority had AGA.

Androgenetic alopecia

The characteristic follicular features on Trichoscopy observed in AGA were Peripilar sign, yellow dots and empty hair follicles. The characteristic hair shaft pattern observed was vellus hair. Variation in hair shaft diameter was more prevalent in fronto-temporal areas.

Telogen effluvium

TE is said to be a disease of exclusion on Trichoscopy. The characteristic finding is that the variation in hair – shaft diameter is prevalent in fronto-temporal (15%) and occipital areas (65%). It is important to differentiate this condition from AGA, where-in the variation in hair shaft thickness is present in fronto-temporal areas and absent in occipital area. The follicular features present in TE are Peripilar sign, yellow dots and vellus hair.

Trichoscopy is a handy tool and proves to be of value in difficult to diagnose/atypical scalp conditions. It is also of prognostic value and will most likely prove to be an indispensable tool in modern practice of the skin and hair sciences.

References

- Tosti A, Duque-Estrada B. Dermoscopy in hair disorders. *J Egypt Women Dermatol Soc* 2010;7:1-4.
- Valia R, Valia A. IADVL textbook of Dermatology. 3rd Edition. Bhalani Publishing House, Mumbai, India 2010, 887.
- Dhurat R, Saraogi P. *Int J Trichology* 2009;1(2):108-119.
- Jain N, Doshi B, Khopkar U. *Int J Trichology* 2013;5(4):170-178.
- Rudnicka L, Olszewska M, Rakowska A, Kowalska-Oledzka E, Slowinska M. Trichoscopy: A new method for diagnosing hair loss. *J Drugs Dermatol* 2008;7:651-4.
- Tosti A. Hair shaft disorders. In: Tosti A, editor. *Dermoscopy of hair and scalp: Pathological and clinical correlation*. Illustrated ed. USA. CRC press; 2007, 51-3.
- Pedrosa A, Morais P, Lisboa C, Azevedo F. The importance of trichoscopy in clinical practice. *Dermatology Research and Practice*. 2013, Article ID 986970, 3 pages [22 Sep 2015]. <http://dx.doi.org/10.1155/2013/986970>
- Tanaka M. Dry dermoscopy is useful to observe tertiary structures of skin surface such as hairs. *Dermoscopy J Dermatol* 2006;33:513-7.
- Tanaka M. With or without gel. In: Tanaka M, Ohara K, editors. *Dermoscopy handbook*. 1st ed. Tokyo: Shujunsha 2005, 40-1.
- Tosti A, Torres F. Dermoscopy in the diagnosis of hair and scalp disorders. *Actas Dermosifiliogr*. 2009;100(1):114-9.
- Rudnicka L, Ozewska M, Rakowska A. Acquired non-scarring alopecia. In: Rudnicka L, Olszewska M, Rakowska A, editors. *Atlas of Trichoscopy: Dermoscopy in hair and scalp Disease*. 2nd ed. London: Springer-Verlag 2012, 205-275.

12. Lacarrubba F, Dall'Oglio F, Rita Nasca M, Micali G. Videodermoscopy enhances diagnostic capability in some forms of hair loss. *Am J Clin Dermatol* 2004;5:205-8.
13. Ross EK, Vincenzi C, Tosti A. Videodermoscopy in the evaluation of hair and scalp disorders. *J Am Acad Dermatol* 2006;55:799-806.
14. Duque-Estrada B, Tamler C, Sodré CT, Barcaui CB, Pereira FB. Dermoscopy patterns of cicatricial alopecia resulting from discoid lupus erythematosus and lichen planopilaris. *An Bras Dermatol* 2010;85:179-83.