



# International Journal of Dermatology, Venereology and Leprosy Sciences

E-ISSN: 2664-942X  
P-ISSN: 2664-9411  
[www.dermatologypaper.com](http://www.dermatologypaper.com)  
Derma 2021; 4(1): 14-16  
Received: 15-10-2020  
Accepted: 19-12-2020

**Deepika Agarwal**  
Assistant Professor,  
Department of Dermatology,  
Hind Institute of Medical  
Sciences Ataria Sitapur,  
Uttar Pradesh, India

**Kanchan Srivastava**  
Assistant Professor,  
Department of Dermatology,  
Hind Institute of Medical  
Sciences Ataria Sitapur,  
Uttar Pradesh, India

**Dr. Himali Tandon**  
Assistant Professor,  
Department of Dermatology,  
Hind Institute of Medical  
Sciences Ataria Sitapur,  
Uttar Pradesh, India

**Corresponding Author:**  
**Dr. Himali Tandon**  
Assistant Professor,  
Department of Dermatology,  
Hind Institute of Medical  
Sciences Ataria Sitapur,  
Uttar Pradesh, India

## Assessment of cases of primary cutaneous lymphomas- A clinical study

**Deepika Agarwal, Kanchan Srivastava and Dr. Himali Tandon**

**DOI:** <https://doi.org/10.33545/26649411.2021.v4.i1a.56>

### Abstract

**Background:** Primary cutaneous lymphomas represent the second most common group of extranodal non-Hodgkin lymphoma after primary gastrointestinal lymphomas. The present study was conducted to assess cases of primary cutaneous lymphomas.

**Materials and methods:** 82 cases of primary cutaneous lymphomas both genders were recruited. Duration of illness, presence of pruritus, family history, and occupational history was recorded.

**Results:** Out of 82 patients, males were 48 and females were 34. Type of lesions were mycosis fungoides in 42, adult T-cell lymphoma/leukemia in 30 and peripheral T-cell lymphoma in 10 patients. Type of lesions were macules in 16, papules in 20, plaques in 22, macules & papules in 10, papules & plaques in 4, pustules and nodules in 6, plaques and nodules in 4 cases. The difference was significant ( $P < 0.05$ ).

**Conclusion:** Type of lesions were mycosis fungoides, adult T-cell lymphoma/leukemia and peripheral T-cell lymphoma in 10 patients. Type of lesions were macules, papules, plaques, macules & papules.

**Keywords:** Mycosis fungoides, adult T-cell lymphoma/leukemia and peripheral T-cell lymphoma

### 1. Introduction

Cutaneous lymphomas refer to the clonal proliferation of T or B lymphocytes and rarely of natural killer cells or plasmacytoid dendritic cells. Primary cutaneous lymphomas represent the second most common group of extranodal non-Hodgkin lymphoma after primary gastrointestinal lymphomas<sup>[1]</sup>. Sixty-five percent of cutaneous lymphomas are of T-cells unlike nodal lymphomas where B-cells predominate. The incidence of cutaneous lymphomas is showing an ascending trend which could be due to both improved diagnosis, as well as a genuine increase in disease incidence<sup>[2]</sup>.

Primary cutaneous T cell lymphomas is a heterogenous group of diseases with varied clinical presentations and prognosis. An annual incidence rate of new cases of cutaneous lymphomas of 1 in 100,000 people is estimated to occur in the United States<sup>[3]</sup>. Of primary cutaneous lymphomas, 75% are T-cell lymphomas, 25% are B-cell lymphomas, and less than 1% are NK-cell lymphomas<sup>[4]</sup>. Males are more affected than females, with a male to female ratio of 2 or 3 to 1. The mean age at diagnosis is between 50 and 60 years of age; however, the disease may also occur in childhood. The use of new molecular, histological, and clinical criteria have enhanced the recognition of primary cutaneous T- and B-cell lymphomas. Compared to their nodal counterpart they have a different clinical behavior and therefore require a different treatment approach<sup>[5]</sup>. The present study was conducted to assess cases of primary Cutaneous lymphomas.

### 2. Materials and Methods

The present study was conducted on 82 cases of primary cutaneous lymphomas of both genders. Enrolment of patients was done after obtaining their consent.

Data such as name, age, gender etc. was recorded. Duration of illness, presence of pruritus, family history, and occupational history. Peripheral smear was evaluated for the total number of white blood cells, percentage of lymphocytes and atypical lymphocytes. Five milliliters of blood was collected and screened for human T-cell lymphotropic virus-1 (HTLV-1) antibodies.

The diagnosis of the lymphoma type was established according to the World Health Organization/European Organization for Research and Treatment of Cancer (WHO/EORTC) classification 2005 and the data were analysis statistically. P value less than 0.05 was considered significant.

**3. Results**

**Table 1:** Distribution of patients

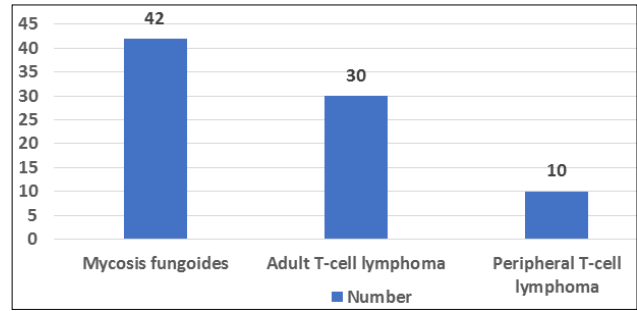
Total- 82		
Gender	Males	Females
Number	48	34

Table 1 shows that out of 82 patients, males were 48 and females were 34.

**Table 2:** Primary cutaneous lymphomas

Types	Number	P value
Mycosis fungoides	42	0.01
Adult T-cell lymphoma	30	
Peripheral T-cell lymphoma	10	

Table 2, Figure 1 shows that type of lesions were mycosis fungoides in 42, adult T-cell lymphoma/leukemia in 30 and peripheral T-cell lymphoma in 10 patients. The difference was significant ( $P < 0.05$ ).

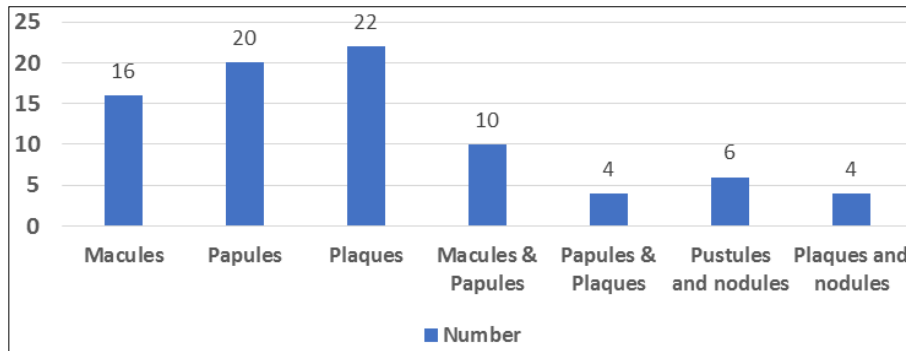


**Fig 1:** Primary cutaneous lymphomas

**Table 3:** Type and frequency of skin lesions

Type	Number	P value
Macules	16	0.02
Papules	20	
Plaques	22	
Macules & Papules	10	
Papules & Plaques	4	
Pustules and nodules	6	
Plaques and nodules	4	

Table 3, Figure 2 shows that type of lesions were macules in 16, papules in 20, plaques in 22, macules & papules in 10, papules & plaques in 4, pustules and nodules in 6, plaques and nodules in 4 cases. The difference was significant ( $P < 0.05$ ).



**Fig 2:** Type and frequency of skin lesions

**Table 4:** Site of lesions

Site	Percentage	P value
Scalp	40%	0.01
Face	25%	
Chest	12%	
Back	23%	

Table 4 shows that common sites were scalp in 40%, face in 25%, Chest in 12% and cack in 23%. The difference was significant ( $P < 0.05$ ).

**4. Discussion**

The diagnosis of primary cutaneous lymphomas is confirmed by a histopathology analysis, with neoplastic lymphocytes infiltrating the epidermis, dermis, and/or subcutaneous tissue. However, the immunohistochemical examination is essential to complement the classification of cutaneous lymphomas [6]. It initially differentiates among T, B, and NK cell lymphomas and then assists in classifying among these groups [7]. The search for the clonality of the TCR gene (T lymphocytes) or the heavy chains of immunoglobulins (B lymphocytes) is performed by

polymerase chain reaction (PCR) or Southern blot and allows the detection of monoclonal populations, which are highly suggestive of malignant lymphoproliferative disorders. The search for clonality is a useful tool for differentiation between reactive lymphoproliferative processes (pseudolymphoma) and lymphomas [8]. The present study was conducted to assess cases of primary cutaneous lymphomas.

In present study, out of 82 patients, males were 48 and females were 34. We found that type of lesions were mycosis fungoides in 42, adult T-cell lymphoma/leukemia in 30 and peripheral T-cell lymphoma in 10 patients. Khader *et al.* [9] conducted a study among 35 cases, 33 (94.3%) were T-cell, and 2 (5.7%) were B-cell lymphomas. The mean age was 52.66, and the male to female ratio was 2.5:1. The most common types of T-cell lymphomas included mycosis fungoides (MF) (57.1%) followed by adult T-cell lymphoma/leukemia (ATL) (17.1%). Primary cutaneous peripheral T-cell lymphoma not otherwise specified was diagnosed in 17.1% and anaplastic large cell lymphoma in 2.9%. The morphological types of MF included polymorphic, poikilodermatous, folliculotropic,

hypopigmented, hyperpigmented, mixed and purpuric. Skin manifestations of ATL included ulcerated plaques and erythroderma. Epidermotropism was very marked in ATL (83.3%) than in MF (70%). Larger Pautrier's microabscess was noted in ATL compared to smaller ones in MF. Markedly dense, diffuse infiltrate of atypical cells was noted in ATL in contrast to mild to moderate nodular or perivascular infiltrate in MF. ATL had an extremely poor prognosis.

We found that type of lesions were macules in 16, papules in 20, plaques in 22, macules & papules in 10, papules & plaques in 4, pustules and nodules in 6, plaques and nodules in 4 cases. We observed that common sites were scalp in 40%, face in 25%, Chest in 12% and cack in 23%.

Mycosis fungoides (MF) is the most prevalent cutaneous T-cell lymphoma (CTCL), corresponding to about 50% of all cutaneous lymphomas. It is a CD4+ effector memory T-cell neoplasm. MF is the only primary cutaneous lymphoma with no primary lymph node malignancy counterpart<sup>[10]</sup>. Indolent neoplasm with insidious progression can suffer a transformation to an aggressive large-cell lymphoma. It is composed of different clinical variants and characterized by marked epidermotropism<sup>[11]</sup>. Exposure to chemical agents like aromatic halogenated hydrocarbons in the petroleum, wood and textile industries, organochlorines in pesticides and paints, radiation, and tobacco are thought to be major risk factors for cutaneous T-cell lymphoma, especially MF. Other reported immunophenotypic variants of MF include CD4/CD8 double negative, CD45RA+, and CD20+. The former ones behave similar to classic MF although the latter appears to exhibit an aggressive clinical course. A single case of CD4/8 double negative MF in our study presented with hyperpigmented plaques and nodules and progressed to leukemic MF<sup>[12]</sup>.

## 5. Conclusion

Authors found that type of lesions were mycosis fungoides, adult T-cell lymphoma/leukemia and peripheral T-cell lymphoma in 10 patients. Type of lesions were macules, papules, plaques, macules & papules.

## 6. References

1. Samimi S, Rook AH, Kim EJ. Update on epidemiology of cutaneous T-cell lymphoma. *Curr Derm Rep* 2013; 2:35-41
2. Pavlovsky L, Mimouni D, Amitay-Laish I, Feinmesser M, David M, Hodak E. Hyperpigmented mycosis fungoides: An unusual variant of cutaneous T-cell lymphoma with a frequent CD8 + phenotype. *J Am Acad Dermatol* 2012; 67:69-75.
3. Al-Abdulrazzaq A, Zadeh VB, Al-Otaibi S, Najem N. Purpuric mycosis fungoides: A rare presentation of a great masquerade. *Gulf J Dermatol Venereol* 2011; 18:47-9.
4. Thompson D, Whittaker S. Cutaneous manifestations of HTLV-1. *J Am Acad Dermatol* 2006; 54(3):153.
5. Chan HL, Su IJ, Kuo TT, Kuan YZ, Chen MJ, Shih LY *et al.* Cutaneous manifestations of adult T cell leukemia/lymphoma. Report of three different forms. *J Am Acad Dermatol* 1985; 13:213-9.
6. Kawakami T, Kawanabe T, Soma Y. Granuloma annulare-like skin lesions as an initial manifestation in a Japanese patient with adult T-cell leukemia/lymphoma. *J Am Acad Dermatol* 2009; 60:848-52.

7. Sumida H, Sugaya M, Kamata M, Suga H, Miyagaki T, Ohmatsu H *et al.* Lichen planus-like lesions as the first manifestation of adult T-cell leukaemia/lymphoma. *Acta Derm Venereol* 2013; 93:461-3.
8. Manabe T, Hirokawa M, Sugihara K, Sugihara T, Kohda M. Angiocentric and angiodestructive infiltration of adult T-cell leukemia/lymphoma (ATLL) in the skin. Report of two cases. *Am J Dermatopathol* 1988; 10:487-96.
9. Khader A, Manakkad SP, Shaan M, Pillai SS, Riyaz N, Manikoth PB *et al.* A clinicopathological analysis of primary cutaneous lymphomas: A 6-year observational study at a tertiary care center of south India. *Indian J Dermatol* 2016; 61:608-17.
10. Whittaker SJ, Child S. Cutaneous lymphomas. In: Griffiths C, Barker J, Bleiker T, Chalmers R, Creamer D, editors. *Rook's Text Book of Dermatology*. 9th ed. UK: Wiley-Blackwell; 2016; 140:39.
11. Willemze R, Jaffe ES, Burg G, Cerroni L, Berti E, Swerdlow SH *et al.* WHO-EORTC classification for cutaneous lymphomas. *Blood* 2005; 105:3768-85.
12. Doshi BR, Khopkar US. Retrospective study of spectrum of cutaneous lymphoma presenting to dermatology. *Indian J Dermatol Venereol Leprol* 2011; 77:512-5.