



# International Journal of Dermatology, Venereology and Leprosy Sciences

E-ISSN: 2664-942X  
P-ISSN: 2664-9411  
[www.dermatologypaper.com/](http://www.dermatologypaper.com/)  
Derma 2020; 3(1): 01-03  
Received: 02-11-2019  
Accepted: 04-12-2019

**Dr. Avinash Kumar**  
Department of Dermatology,  
Nepal Medical College Basic  
Building Campus,  
Gokarneshwar, Nepal

## Analysis of cases of Subungual splinter hemorrhage in study group

**Dr. Avinash Kumar**

DOI: <https://doi.org/10.33545/26649411.2020.v3.i1a.29>

### Abstract

**Introduction:** Subungual splinter hemorrhage (SSH) is a common nail disease, it has been estimated that the prevalence of SSH is around 19%. The present study recorded Subungual splinter hemorrhage in study group.

**Materials & Methods:** The present study was conducted on 104 cases of Subungual splinter hemorrhage of both genders. In all cases, the clinical and dermoscopic characteristics and comorbidities were recorded.

**Results:** Age group 18-30 years had 28, 30-50 years had 52 and >50 years had 24 cases. The difference was significant ( $P < 0.05$ ). Common comorbidities in cases was tinea pedis in 2, Onychomycosis in 5, Pemphigus vulgaris in 1, Paronychia in 6 and Systemic lupus erythematosus in 2 cases. The difference was significant ( $P < 0.05$ ). Common site was left or right first toenail was seen in 92.1%, left or right second fingernail in 4.5% and left or right third fingernail in 3.4%. The difference was significant ( $P < 0.05$ ).

**Conclusion:** Authors found that comorbidities in cases were tinea pedis, Onychomycosis, Pemphigus vulgaris, Paronychia and Systemic lupus erythematosus.

**Keywords:** Pemphigus vulgaris, Subungual splinter hemorrhage, Systemic lupus erythematosus

### Introduction

Subungual splinter hemorrhage (SSH) is a common nail disease, it has been estimated that the prevalence of SSH is around 19%, and there are statistically greater incidence in male than in female and in African-Americans than in White healthy individuals [1]. Notably, SSH was documented in a range of 11%–20% in hemodialysis patients. Usually, SSH was regarded as an early sign of thromboangiitis obliterans and a new sign of the antiphospholipid coagulopathy. In the clinic, it is difficult to differ SSH from other nail diseases, especially subungual malignant melanoma and melanonychia due to their similar characteristics [2].

The blood attaches itself to the underlying nail plate and moves distally. Splinter hemorrhages occasionally appear to remain stationary, because of attachment to the nail bed rather than to the plate [3]. In severe cases, loosening of the nail plate with separation of the nail from the nail bed can occur. Although trauma is the most common cause of splinter hemorrhages, they may also be caused by several systemic illnesses, including cardiovascular (subacute bacterial endocarditis), renal, pulmonary disease, and diabetes mellitus [4].

Dermatologic conditions associated with splinter hemorrhages include several primary nail disorders, such as onychomycosis and psoriasis. Splinter hemorrhages of unknown etiology have also been reported. Splinter hemorrhages are more common in males than in females and in dark colored individuals than in whites. They are usually confined to a single digit in healthy individuals. Occurrence in women with more than one fingernail affected raises the suspicion of an underlying systemic disease [5]. The present study recorded Subungual splinter hemorrhage in study group.

### Materials & Methods

The present study was conducted in the department of Dermatology. It included 104 cases of Subungual splinter hemorrhage of both genders. All were informed regarding the study and written consent was obtained. Ethical clearance was taken before starting the study.

**Corresponding Author:**  
**Dr. Avinash Kumar**  
Department of Dermatology,  
Nepal Medical College Basic  
Building Campus,  
Gokarneshwar, Nepal

General information such as name, age, etc. was recorded. In all cases, the clinical and dermoscopic characteristics and comorbidities were recorded. Results thus obtained were subjected to statistical analysis. P value less than 0.05 was considered significant.

**Results**

**Table I:** Age wise distribution of patients

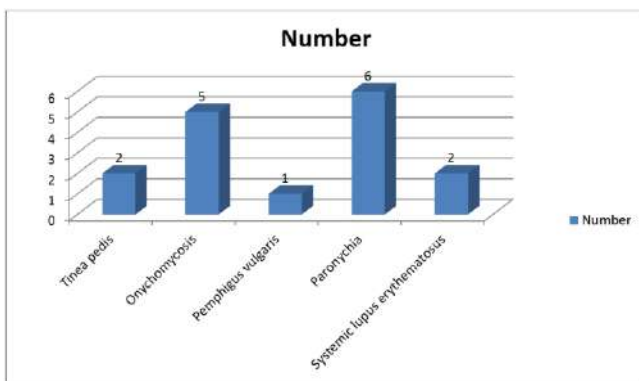
Age group	Number	P value
18-30 years	28	0.01
30- 50 years	52	
>50 years	24	
Total	104	

Table I shows that age group 18-30 years had 28, 30-50 years had 52 and >50 years had 24 cases. The difference was significant ( $P < 0.05$ ).

**Table II:** Comorbidities in cases

Comorbidities	Number	P value
Tinea pedis	2	0.05
Onychomycosis	5	
Pemphigus vulgaris	1	
Paronychia	6	
Systemic lupus erythematosus	2	

Table II, graph I shows that common comorbidities in cases was tinea pedis in 2, Onychomycosis in 5, Pemphigus vulgaris in 1, Paronychia in 6 and Systemic lupus erythematosus in 2 cases. The difference was significant ( $P < 0.05$ ).



**Graph I:** Comorbidities in cases

**Table III:** Site of occurrence

Site	Percentage	P value
Left or right first toenail	92.1	
Left or right second fingernail	4.5	
Left or right third fingernail	3.4	

Table III shows that common site was left or right first toenail was seen in 92.1%, left or right second fingernail in 4.5% and left or right third fingernail in 3.4%. The difference was significant ( $P < 0.05$ ).

**Discussion**

Splinter hemorrhages may be caused by a variety of conditions including physical factors, dermatologic diseases, systemic diseases, and drugs. Trauma to the nail unit is one of the most common causes of onychodystrophy

[6]. Splinter hemorrhages may arise from a single blow or result from frequent minor stresses. Immediate effects of acute trauma include splinter hemorrhages, subungual hematomas, and nail shedding. Various physical activities that are likely to involve trauma to the extremities include sports, housework, gardening, hobbies, playing of percussion instruments, and habit tics [7].

Some dermatological conditions such as psoriasis, dermatitis, and fungal infections (onychomycosis) are associated with splinter hemorrhages. Farber described subungual splinter hemorrhages as a characteristic finding in nail psoriasis, perhaps analogous to the Auspitz sign (i.e., multiple fine bleeding points when a scale is removed from a psoriatic plaque, caused by thinning of the epidermis over the dermal papillae) [8]. The present study recorded Subungual splinter hemorrhage in study group.

In this study, age group 18-30 years had 28, 30-50 years had 52 and >50 years had 24 cases. Common comorbidities in cases was tinea pedis in 2, Onychomycosis in 5, Pemphigus vulgaris in 1, Paronychia in 6 and Systemic lupus erythematosus in 2 cases. Gao *et al.* [9] conducted a study in which sixty-three SSH patients were included with an age range of 17-58 years. Nearly 93.7% of SSH patients occurred in the right, left, or right and left first toenails; 66.7% of SSH patients occurred only in one toenail; there were 60.3% of SSH patients with a clear stimulus causing it and 31.8% of SSH patients with five types of comorbidities.

The common characteristics of dermoscopy showed a reddish brown or brown stain with a clear boundary visible under the nail in which the color gradually faded outward from the center, with no blue or white structure. After following up for 24 weeks, the disappearance of hemorrhage was observed in 95.2% of SSH patients. For the recovered SSH patients, data analysis showed no significant difference in the course of SSH in males and females; the statistical analysis showed that there was no significant correlation between age and course in recovered SSH patients.

We observed that common site was left or right first toenail was seen in 92.1%, left or right second fingernail in 4.5% and left or right third fingernail in 3.4%. The goal of most SSH patients going to hospital to visit doctor are to exclude subungual malignant melanoma or melanonychia. In these cases, dermoscopy may be a good choice when making clinical observations. Dermoscopy can initially identify different nail diseases. SSH presents with an irregular black-red or brown-stained appearance, melanonychia with brown or black vertical regular line, and malignant melanomas are characterized by dermoscopy [10].

Classical lesions associated with subacute bacterial endocarditis include petechiae and splinter hemorrhages. Splinter hemorrhages associated with endocarditis may represent damage from inflammation of the blood vessels (vasculitis), or microscopic clots that damage the small capillaries (microemboli). Nonetheless, subungual splinter hemorrhages in patients with minimal supporting evidence for bacterial endocarditis by history, physical examination, or laboratory tests, in the face of negative blood cultures, have no clinical significance. Subungual splinter hemorrhages can also be seen in the antiphospholipid syndrome. Furthermore, a patient with cholesterol crystal embolization demonstrated splinter hemorrhages of multiple fingernails and toenails as part of her clinical presentation [11].

**Conclusion**

Authors found that comorbidities in cases were tinea pedis, Onychomycosis, Pemphigus vulgaris, Paronychia and Systemic lupus erythematosus.

**References**

1. Gross NJ, Tall R. Clinical significance of splinter haemorrhages. *Br Med J*. 1963; 2:1496-8.
2. Kilpatrick ZM, Greenberg PA, Sanford JP. Splinter hemorrhages – Their clinical significance. *Arch Intern Med*. 1965; 115:730-5.
3. Tercedor J, López Hernández B, Manuel Ródenas J. Nail diseases in haemodialysis patients: Case-control study. *Br J Dermatol*. 2001; 144:445-6.
4. Blum M, Aviram A. Splinter hemorrhages in patients receiving regular hemodialysis. *JAMA*. 1978; 239:47.
5. Quenneville JG, Gossard D. Subungueal-splinter hemorrhage an early sign of thromboangiitis obliterans. *Angiology*. 1981; 32:424-32.
6. Asherson RA. Subungual splinter haemorrhages: A new sign of the antiphospholipid coagulopathy? *Ann Rheum Dis*. 1990; 49:268.
7. Akay BN, Heper AO, Thomas L, Balme B, Clark S, Rosendahl C *et al*. Nail apparatus melanoma initially diagnosed as nail matrix blue nevus: A case report with dermatoscopy and dermatopathology. *Dermatol Pract Concept*. 2017; 7:63-6.
8. Alessandrini A, Starace M, Piraccini BM. Dermoscopy in the evaluation of nail disorders. *Skin Appendage Disord*. 2017; 3:70-82.
9. Gao J, Shen C, Ko R, Guo Y, Shen X, Cui Y *et al*. Clinical observation and follow-up of subungual splinter hemorrhages of toenails in Chinese adults. *Indian J Dermatol*. 2020; 65:11-6.
10. Yang HP, Jia H, Lu ZZ, Sun JF. Pemphigus vulgaris comorbid with subungual splinter hemorrhages: A case report. *Chinese J Dermatol*. 1998; 31:1.
11. Li YY, Su Y. Pemphigus vulgaris comorbid with subungual splinter hemorrhages: A case report. *Chin J Derm Venereol*. 2005; 38:422